

Ophthalmology course

This last October Dr. Mehdi & Dr. Ellen attended an ophthalmology course presented by Dr. Izak Venter of the Johannesburg Animal Eye Hospital in South Africa. The course was organized by the British Veterinary Centre in Abu Dhabi and held in the premises of the Veterinary Hospital in Dubai. It was therefore a mutual effort of several veterinary clinics in the UAE to keep their skills up-to-date and to continue education whilst being abroad.

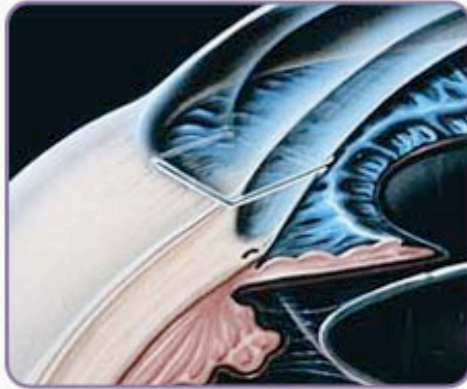
Dr. Venter is a well known professional in his country and an excellent teacher. The course took us back to the basics and Dr. Venter, as a refresher took us by the hand through the correct ophthalmologic exam and later on showed us some more detailed problems and work-ups of patients with more advanced problems. We had some excellent patients brought in (including my own dog Dutch) to be willing models for us to practice on and fortunately both patients turned out healthy with just some aging eye changes.

Besides the straight forward exam and strategic work-up of more difficult problems, we also discussed the new developments in eye-examination and treatment such as Ultrasonography, computerized digital photography of the retina, ophthalmic nerve and posterior eye chamber, which shone clear light on helping us diagnosing and differentiating more serious problems at an earlier age, hence hopefully being able to prevent the worst from happening. Whilst we do not have all this advanced equipment yet, we will be investigating the possibilities to bring this equipment into our clinic.

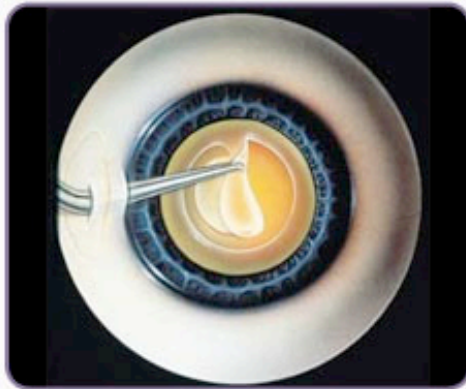
On a regular basis we will be contacting Dr. Venter for advice on eye problems in patients of our clinic so you can rest assured that if your pet comes down with eye problems, we are there to help and the ophthalmology specialist is only an e-mail/phone call away.

Regards,

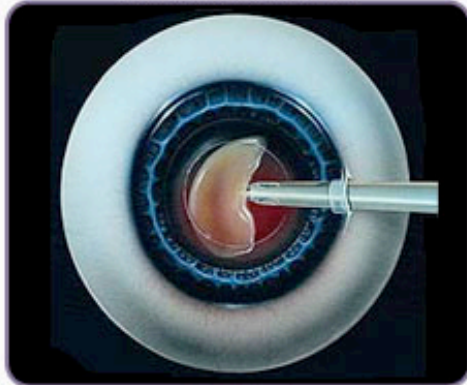
Ellen Kruijning



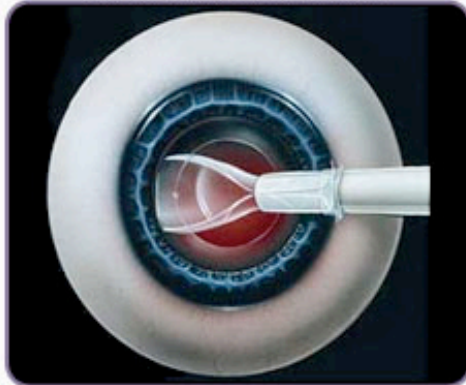
Clear corneal incision



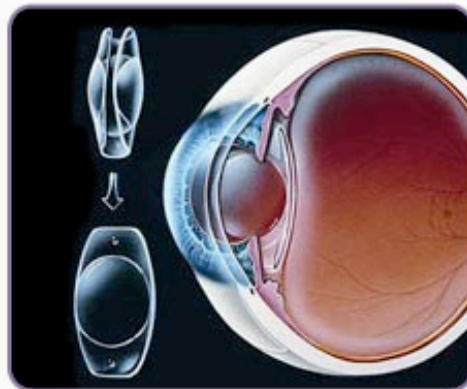
Making the capsulorhexis



Ultrasound removal of the lens



Inserting IOL cartridge



IOL unfolding in the eye

Images courtesy Dr. Izak Venter (The diagrams above show the sequence of steps in cataract surgery)